

VARIATIONS IN PLACENTAL ATTACHMENT OF UMBILICAL CORD AND ITS CLINICAL CORRELATIONSM. Yousuf Sarwar¹, Tarannum Yasmin², Nawal Kishor Pandey³**HOW TO CITE THIS ARTICLE:**

M. Yousuf Sarwar, Tarannum Yasmin, Nawal Kishor Pandey. "Variations in Placental Attachment of Umbilical Cord and Its Clinical Correlations". Journal of Evolution of Medical and Dental Sciences 2015; Vol. 4, Issue 70, August 31; Page: 12120-12124, DOI: 10.14260/jemds/2015/1746

ABSTRACT: The umbilical cord is a narrow tube like structure that forms connecting link between foetus and placenta. The umbilical cord begins to form at five weeks after conception, becomes progressively longer until 28 weeks of pregnancy contains two arteries and one vein surrounded by wharton's jelly enclosed in a layer of amnion. Abnormalities in the development and site of attachment of umbilical cord can cause problems which have the potential to affect maternal and foetal health.

AIMS AND OBJECTIVES: The purpose of this study is to analyze the site of attachment of umbilical cord to the placenta by dissection method and to correlate them with any abnormalities of the mother and foetus. **MATERIALS AND METHODS:** A total of 150 specimens were collected from Katihar Medical College during the period of 2014-2015 and subjected to thorough examination. Details were recorded and analyzed. **RESULTS:** Study showed Eccentric attachment of umbilical cord 66%, Central attachment 24%, Marginal 08% and Velamentous 02%. **CONCLUSION:** Variations in the placental attachment of umbilical cord are also associated with abnormalities in the foetus as well as the mother. Early examination of the placenta can yield information that may be important in the immediate and later management of mother and infant.

KEYWORDS: Umbilical cord, Attachment, Eccentric, Marginal.

INTRODUCTION: The umbilical cord is a narrow tube-like structure which connects the developing baby to the fetal surface of placenta. The umbilical cord contains three blood vessels; two arteries and one vein surrounded by Wharton's Jelly all enclosed in a layer of amnion. The deoxygenated foetal blood leaves the foetus in two umbilical arteries that pass through the umbilical cord. When they reach the foetal surface of the placenta, these vessels divide into many branches which enter the chorionic villi. The oxygenated blood returns to the foetus via the venules and veins in the chorionic villi that join to form the umbilical vein. The umbilical cord begins to form at five weeks after conception which becomes progressively longer until 28 weeks of gestation, reaching an average length of 55-65 cm long with outer amniotic epithelium.

Microscopically the umbilical cord arteries composed of double layered muscular wall, no internal elastic lamina while the umbilical vein larger in diameter, thin wall with single layer of disorganized circular smooth muscle and an internal elastic lamina.

The cord deserves attention right from the first trimester. A number of abnormalities in the development and site of insertion can affect the umbilical cords which have the potential to affect maternal and foetal health.

Variations in the attachment of umbilical cord are thought to result from the process known as trophotropism in which the chorionic frondorum or the early placenta 'migrate' with advancing gestation to ensure a better blood supply from a richly vascularized area. The umbilical cord insertion to the placenta is divided as central/ eccentric, marginal and velamentous as it relates to the chorionic plate. Another type of variation is furcate insertion in which umbilical cord branch before its insertion to placenta.

ORIGINAL ARTICLE

If the umbilical cord is inserted within 2 cm from the placental edge, it is considered as marginal attachment. This is associated with IUGR, preterm labour. In velamentous type cord insertion to the chorio-amniotic membrane of placenta. This anomaly is associated with low birth weight, low apgar score, growth retardation, oesophageal atresia, spina bifida, VSD. Furcate placenta has greater volume than normal villi, villous trophoblast and syncytial knots. Furcate placenta is more prone to early delivery because they are heavier more voluminous villi with more trophoblast & syncytial knots.

MATERIALS AND METHODS: The materials for the study were collected from the obstetrics and gynecology department of Katihar Medical College, Katihar, Bihar and the work has been conducted in the department of Anatomy during the year 2014-2015. A total of 150 normal specimens of placenta with intact umbilical cord were collected and preserved in 10% formalin.

The specimens were cleared, dissected and observed for placental attachment of umbilical cord. Variations in site of attachment of umbilical cord were noted in all the specimens and measured its distance from the placental margin and photographed. Distance were recorded and analyzed.

RESULTS: In all specimens the pattern of placental attachment of umbilical cord were observed and studied. Among the 150 specimen, 99(66%) placenta showed the Eccentric and 36(24%) Central attachment of umbilical cord which was considered as normal. Marginal insertion 12(08%) and velamentous 03(02%) from the total observed placentae.

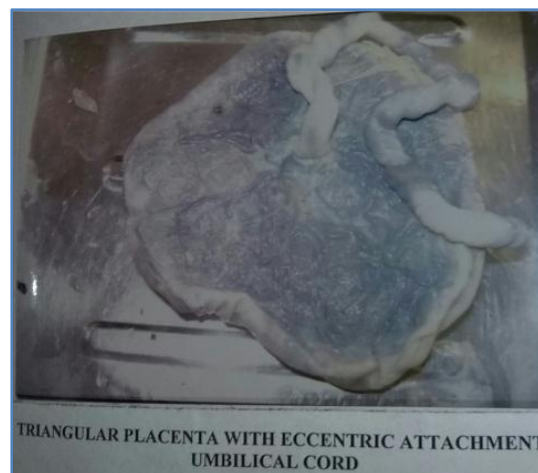
Battledore placentae were associated with the anomalies of placenta as well as related to abnormal conditions of the mother and foetus. More number of abnormalities in foetus was seen in placentae with abnormalities compared with normal placentae.

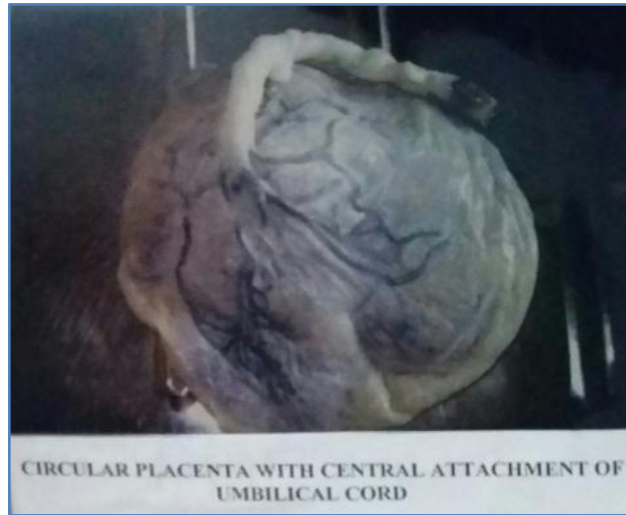
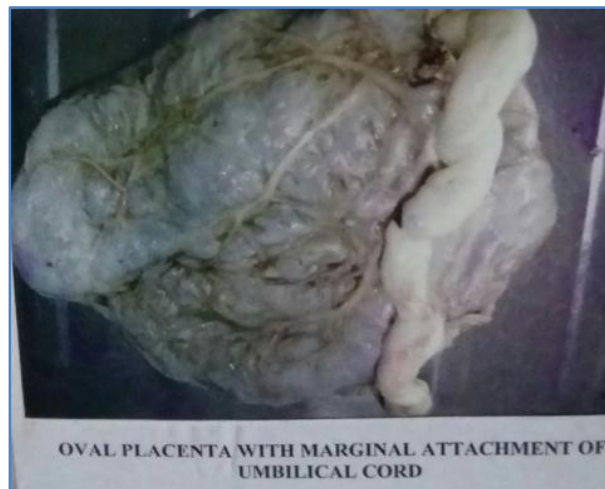Site of Umbilical Cord Insertion	Number	Percent %
Eccentric	99	66%
Central	36	24%
Marginal	12	08%
Velamentous	3	02%

Table 1: Gross observation of umbilical cord

Fig. 1: Site of insertion of umbilical cord.

A- Eccentric:



B- Central:**C- Marginal:**

DISCUSSION: Abnormalities in the placental insertion of umbilical cord has been associated with number of complication of pregnancy and foetal outcome due to compression of umbilical vessels. These abnormalities are also associated with IUGR, preterm labour, oesophageal atresia, VSD, spina bifida and so on.

In the present study we have evaluated the variation in placental attachment of umbilical cord which may be clinically important as stated earlier.

Among the 150 specimen, 99(66%) showed eccentric attachment, 36(24%) central and 12(08%) were marginal and rest 3(02%) were velamentous insertion of umbilical cord.

Donald N Di Salvo et al conducted sonographic studies and observed 38(70.37%) normal insertion, 12(22.2%) marginal and 4(7.41%) velamentous insertion.

W. Sepulveda et al assessed the placental insertion of umbilical cord in 138 specimens by ultrasonography and reported 127(92.02%) normal, 10(7.2%) marginal and 1(0.75%) velamentous type of cord insertion.

ORIGINAL ARTICLE

Variation (Eccentric, marginal and velamentous) in the placental attachment of umbilical cord is probably as a result of trophotrophism.

Among 12 battledore placenta, there is history of abortion in 2, type 2 diabetes mellitus in 1, preeclampsia in 1 and anencephaly in 1 specimen.

Among 3 velamentous placentae, type 2 diabetes mellitus is associated in 1 case. Battledore placentae were associated with the anomalies of placentae as well as related to abnormal conditions of the mother and foetus.

CONCLUSION: Variations in the placental attachment of umbilical cord are associated with abnormalities in the foetus as well as the mother. Early prenatal diagnosis of umbilical cord insertion anomalies gives an insight into the congenital anomalies. Abnormal placental attachments of umbilical cord are one of the causes of intrauterine death of foetus due to tear of umbilical vessels during labour.

Therefore, it is essential that the delivering physician performs a thorough, accurate examination of the placenta and in case of doubt; radiologist or anatomist should be consulted to confirm the diagnosis. Such early examination of the placentae can yield information that may be important in the immediate and later management of mother and foetus.

REFERENCES:

1. Arun Kinare. Fetal environment. *Indian J Radiol Imaging* Nov 2008; vol. 18, issue 4: 326-344.
2. Bjoro K Jr. Vascular anomalies of the umbilical cord. I. Obstetrical implications. *Early Hum Dev* 1983; 8: 119.
3. Brody S, Frenkel DA. Marginal insertion of the cord and premature labour. *Am J Obstet Gynecol* 1953; 65: 1305.
4. Cruikshank, D.W. Breech. (2003) *Umbilical cord complication*. Danforth *Obstetric and Gynecology*, 9th edition, Philadelphia, Lippincott Williams and Wilkins, pp 381-395.
5. Collins J H, Collins CL (2000). *The Human Umbilical Cord*. In Kingdom J, Jauniaux E, O'Brien S eds. *The Placenta: basic science and clinical Practice*. London: RCOG Press: 319.
6. Donald N, Di Salvo, Carlo B. Benson, Faye C. Laing. Sonographic evaluation of the placental cord insertion site. *American Journal of Radiology* 1998; 170: 1295-1298.
7. Kouyoumdjian A. Velamentous insertion of the umbilical cord. *Obstet Gynecol* 1980; 56: 737-742.
8. Liu CC, Pretorius DH, Scioscia AI, Hull AD. Sonographic prenatal diagnosis of marginal placental cord insertion: clinical importance. *J Ultrasound Med* 2002; 21: 627-632.
9. McLennan JE. Implications of the eccentricity of Human umbilical Cord. *Am J Obstet Gynecol* 1968; 101: 1124-1130.
10. Paavonen J, Jouttunpaa K, Kangasluoma P et.al. Velamentous insertion of the umbilical cord and vasa previa. *Int J Gynaecol Obstet* 1984; 22: 207-211.
11. Rana J, Ebert G.A, Kappy K.A. (1995) adverse prenatal outcome in patients with abnormal umbilical coiling index. *Obstet. And Gynecol.* 85(4): 573-7.
12. Rolschau J. The relationship between some disorders of the umbilical cord and intrauterine growth retardation. *Acta Obstet Gynecol Scand* 1978; 72 (Suppl): 15.
13. W. Sepulveda, I. Rojas, J. A. Robert et al. Placental detection of velamentous insertion of the umbilical cord: a prospective colour of Doppler ultrasound study. *Ultrasound Obstet Gynecol* 2003; 21: 564-569.

ORIGINAL ARTICLE

14. Waldo Sepulveda MD, Amy E. Wong MD, Luisa Gomez MD et al. improving sonographic evaluation of the umbilical cord at the second-trimester Anatomy scan. J ultrasound Med. 2009; 28: 831-835.

AUTHORS:

1. M. Yousuf Sarwar
2. Tarannum Yasmin
3. Nawal Kishor Pandey

PARTICULARS OF CONTRIBUTORS:

1. Associate Professor, Department of Anatomy, Katihar Medical College, Bihar.
2. Associate Professor, Department of Microbiology, Katihar Medical College, Bihar.
3. Professor, Department of Anatomy, Katihar Medical College, Bihar.

FINANCIAL OR OTHER

COMPETING INTERESTS: None

NAME ADDRESS EMAIL ID OF THE CORRESPONDING AUTHOR:

Dr. M. Yousuf Sarwar,
Department of Anatomy,
Katihar Medical College,
Katihar-854105,
Bihar, India.
E-mail: drmysarwar@gmail.com

Date of Submission: 11/08/2015.
Date of Peer Review: 12/08/2015.
Date of Acceptance: 25/08/2015.
Date of Publishing: 28/08/2015.